

Luiz Ronaldo Alberti*, Denny Fabrício Magalhães Veloso, Leonardo De Souza Vasconcellos, Diego Paim Carvalho Garcia and Andy Petroianu

Post-Graduation course of Santa Casa de Belo Horizonte, Medical School of the Federal University of Minas Gerais, Brazil

Dates: Received: 21 December, 2015; Accepted: 22 January, 2016; Published: 23 January, 2016

*Corresponding author: Prof. Luiz Ronaldo Alberti, Avenida Alfredo Balena, 190, Santa Efigenia, Belo Horizonte, MG 30130-000, Brazil, Tel: (55-31)-3509-4759; Fax: (55-31)-3509-4759; E-mail: luizronaldoa@yahoo.com.br

ISSN: 2640-7795

www.peertechz.com

Keywords: Orchiectomy Adrenal glands; Blood pressure; Blood glucose; Lipids; Rats

Case Report

Morphofunctional and Metabolic Alterations after Orchiectomy

Summary

Objective: To verify alterations in lipid profile, blood glucose and pressure, and morphological aspects of the adrenal gland in animals with hypogonadism secondary to total bilateral epididymectomy and orchiectomy.

Methods: Young and adult male Wistar rats were distributed into the following groups: Group 1 – control, animals submitted only to scrotal incision and suture. Group 2 – animals submitted to total bilateral epididymectomy and orchiectomy. After these operations, studies were carried out to analyze possible repercussions of hypogonadism. In Study A, serum levels of free testosterone were measured, along with the body weight and cortical thickness of the adrenal gland of 30 adult rats. In Study B, serum values of glucose, triglycerides, and total cholesterol, and HDL, LDL and VLDL fractions were measured in 20 young rats and 10 adult rats. In Study C, pressure of the caudal artery was measured by plethysmography in 24 adult animals.

Results: Total bilateral epididymectomy and orchiectomy reduced serum levels of testosterone regardless of the age of the animal, and apparently does not modify macro- or microscopically the morphology of the adrenal gland. Hypogonadism secondary to total bilateral epididymectomy and orchiectomy did not modify the serum values of glucose, total cholesterol, LDL and HDL fractions. However, orchiectomy reduced the blood levels of triglycerides and VLDL cholesterol when performed in young rats. Testosterone deficiency was related to smaller weight gain and increased arterial pressure.

Conclusions: Orchiectomy reduces blood levels of triglycerides and VLDL cholesterol in young rats whereas in adult animals, arterial pressure increasing and smaller weight gain are verified.

Introduction

Testicles continually produce testosterone from puberty until the end of life. This production decreases after 40 years of age, and may reach levels below normal and cause the clinical condition known as androgen deficiency in aging males (ADAM). This clinical picture is manifested by mood fluctuations, reduced intellectual activity, a decrease in libido and quality of erections, depression, besides a decrease in muscle mass and strength. Populational aging creates challenges related to cardiovascular disturbances, decreased working capacity, and increased physical dependency. Androgen deficiency may accompany male aging and be a part of this picture. The literature is still controversial as to androgenic hormonal replacement in all men with reduced testosterone [1-3].

Castration reduces serum levels of testosterone, but it is important to point out how the adrenal glands, secondary producers of this hormone, react to hypogonadism and what influence the hypothalamus-hypophysis axis has in the production of testosterone [3]. The association between testosterone and measurements of arterial pressure, blood glucose, and plasma lipids has not yet been totally established. Hypogonadism is also considered a risk factor for some diseases, such as osteoporosis, osteopenia, hypertriglyceridemia, obesity and arterial hypertension [4-6].

The objective of the present paper was to study the modifications in lipid profile, blood glucose, arterial pressure, and morphological

aspects of the adrenal gland in animals with hypogonadism secondary to total bilateral epididymectomy and orchiectomy.

Material and Methods

This project was carried out in observance of the recommendations of the International Norms for Protection of Animals and was approved by the Ethics Committee of Animal Experimentation.

Male Wistar rats (*Rattus norvegicus albinus*) were used, both young (Y), 30-day-old, and mature adults (M), aged three to four months. The animals were allocated in appropriate cages with up to four rats per cage and kept under room temperature conditions with natural lighting, obeying a murine circadian cycle. They were observed daily and had no restrictions on supply of water and feed.

The initial weight of the young rats varied between 55 and 80 g, and of the adults, it was between 250 and 350 g. The animals were randomly distributed into groups, according to the operative procedure performed. In Group 1, control, the rats were submitted to a simulated operation consisting of opening of the scrotum for exposure and manipulation of the testicles. And in Group 2, they were submitted to total bilateral epididymectomy and orchiectomy.

All rats were anesthetized with an association of ketamine hydrochloride, with a dose of 50 mg/kg body weight and xylazine hydrochloride, with a dose of 5 mg/kg of body weight, intramuscularly in the gluteus region. During the entire period of anesthesia, heart and respiratory rate were observed, besides voluntary movement of



the rats in order to identify the anesthetic level and possible anesthetic complications.

After the operations, the animals were distributed into the following studies in order to answer the issues that were the objective of this project.

Study A: morphology of the adrenal gland

Thirty adult rats were distributed into three groups:

- Group 1 (n = 10), control;
- Group 2i (n = 10), orchiectomy, rats euthanized on the 30th postoperative day, considered the immediate postoperative period (i);
- Group 2l (n = 10), orchiectomy, rats euthanized after eight months postoperatively, during the period considered the late postoperative period (l).

Animals in Groups 1 and 2l were euthanized eight months after the operations in order to measure the serum levels of free testosterone by competitive assay and to evaluate macro- and micro-morphologies of the adrenal glands.

After the 30 day or eight-month follow-up period was concluded, the rats were anesthetized and weighed. In the morning, median laparotomies were performed by layers, and 5 ml sample of blood from the caudal vein was collected to determine the levels of free testosterone. Next, the adrenal glands were removed very carefully in order not to damage them. The animals were euthanized with deepened anesthesia.

The removed glands were processed for the histological study with hematoxylin-eosin to evaluate the general characteristics of the gland, and to establish the limit between the cortical and medullar layers. The thickness of the cortical layer was measured with the help of a lens with a 1 cm ruler marked in tenths of millimeters coupled to the left eyepiece of the optic microscope magnified 40 times.

During the microscopic examination, the adrenal was divided into four quadrants and in each one, the largest measurement of the cortical layer was considered. These four measurements of each gland were recorded for statistical analysis.

Study B: assessment of blood glucose and lipid profile

Forty rats, young (Y) and mature (M), were distributed into the following groups:

- Group 1 Y (n = 10), control, young rats;
- Group 1 A (n = 10), control, adult rats;
- Group 2 Y (n = 10), orchiectomy, young rats;
- Group 2 A (n = 10), orchiectomy, adult rats.

Blood was collected from all animals to measure blood glucose, total cholesterol and fractions, as well as triglycerides five months after the operations. The blood collection occurred after 12 hours of fasting with the animal anesthetized and supine. It was dissected right

femoral vein and held vacuum system punch (Vacuntainer[®], Becton Dickinson, Brazil) 1 ml of blood in a sterile tube with separation gel and bottle covered with aluminum foil to protect from light.

Automatic biochemical analyzer: The samples were immediately processed. Values of total cholesterol (TC) and high-density lipoprotein (HDL) fraction were measured, as well as those of the triglycerides (TG), using the colorimetric dry chemistry method in an automated biochemistry analyzer VITROS[®] 950. Values of very low density lipoprotein (VLDL) and low-density lipoprotein (LDL) cholesterol were calculated following the Friedewald formula: $LDL = CT - HDL - TG/5$ and $VLDL = TG/5$. Blood glucose was measured by the colorimetric method (glucose-oxidase), with the same apparatus.

Study C: mean arterial pressure

Twenty-four adult rats were used, distributed into these groups:

- Group 1 (n = 12), control;
- Group 2 (n = 12), orchiectomy.

Mean arterial pressure was measured in the animals before the operations and during the third post-operative month, in both groups, with a non-invasive method - plethysmograph located on the animal's tail.

The general principle of the method is based on measurement of the amplitude of oscillation of the cuff pressure. Oscillations are caused by blood pressure pulses against the cuff. The average blood pressure is represented by oscillations with greater depth. For this to happen it is necessary to clearly tail vasodilation and thus heating of the animal. Pressure measurements were initiated with manual inflation of the cuff to 200 mmHg. Then, the minimum valve opening pressure gauge and slow reduction of the mercury column up to the middle tail blood pressure, manifested by free fall of the water column in parallel. The procedure lasted approximately 15 seconds.

The whole procedure took place in a calm environment after adaptation of the animal to the method. The training was necessary to reduce the variability of blood pressure measurements. It consisted of two daily sessions over three days simulating the definitive procedure (Whitesall 2004). Each session followed the same routine to heat the rat during 10 minutes in a wooden box to the approximate temperature of 33° C to 34° C. Then the animal was gently led to a tubular container with the following characteristics: 30 cm long, 10 cm or 15 cm in diameter as mouse size, and displaceable front ends to mouse containment and further fenestration for externalization the animal's tail. The tail was adapted to the plethysmograph with a mercury column, which defines the mean blood pressure and liquid level showing the cuff pressure oscillations. On the fourth day, they were made pressure measurements considering satisfactory oscillation of the liquid column that which manifested itself as free falling water. The dog's movement artifacts and their desire not to position themselves appropriately for the measures were considered to invalidate results. The time for measuring the period followed 13 hours to 17 hours.

Measurements of adrenal thickness, body weight, free testosterone, blood glucose, and lipid profile were submitted to the

Kolmogorov-Smirnov test to determine the Gaussian distribution of the data, and to Bartlett's test to identify variances. Next, variance analysis (ANOVA) was performed. In the results with a significant difference, post-testing was done with Tukey multiple comparisons in order to define which groups were different. Wilcoxon test analyzed the measurements of mean pre and post-operative arterial pressure values in Group 2. The results of post-operative arterial pressure of Groups 1 and 2 were compared with Mann-Whitney test. The significance level considered corresponded to the value of $p < 0.05$.

Results

All animals were euthanized at the end of the study and the data obtained were grouped as per the stages of the research project.

Study A: morphology of the adrenal gland

One non-orchietomized adult animal (Group 1) was excluded from the analysis due to a failure in processing the blood sample for testosterone level determination.

In Group 2l, weight gain was smaller than in the Control Group (Table 1). Rats from Group 2i, sacrificed one month after orchietomy, displayed the smallest weights among the three groups, but it should be considered that they died at a younger age, and therefore cannot be compared to the other two groups.

Table 1 shows lower serum levels of testosterone in orchietomized rats relative to the Control. There was no difference between Groups 2i and 2l ($p = 0.41$).

Orchietomy did not modify the histological pattern of the medullar and cortical adrenal layers, according to the histological preparation utilized, hematoxylin-eosin. As to the thickness of the adrenal cortex, ANOVA identified no difference between the groups ($p = 0.54$) as seen in Table 1.

Study B: assessment of blood glucose and lipid profile

Non-orchietomized adult animals were excluded from the analysis (Group 1M) due to a failure in processing the blood samples, leading to hemolysis.

Orchietomy did not modify serum levels of glucose, total cholesterol, and LDL and HDL fractions ($p > 0.05$ for all comparisons). However, when performed in young rats, orchietomy reduced the blood levels of triglycerides and VLDL cholesterol (Table 2).

Study C: mean arterial pressure

Two animals from Group 2 were excluded due to technical difficulties in blood pressure measurement. These rats did not adapt to the method and were restless in the cage.

The orchietomized animals displayed higher arterial pressures than those in the Control Group. There was a post-operative arterial pressure increase relative to the preoperative period in the rats from Group 2 (Table 3).

Discussion

Approximately 98% of the circulating testosterone is bound to plasma proteins, 40% is bound to a hepatic glycoprotein called sex

Table 1: Values (mean \pm mean standard deviation) of body weight, free testosterone and adrenal gland thickness of rats in Groups 1, 2i and 2t.

| Groups | Weight (g) | Free testosterone (pg/ml) | Adrenal thickness (mm) |
|-------------------|---------------|---------------------------|------------------------|
| Group 1 (n = 9) | 546 \pm 37 | 2,132 \pm 948 ** | 0.67 \pm 0.06 |
| Group 2i (n = 10) | 315 \pm 15 | 136 \pm 39 | 0.70 \pm 0.08 |
| Group 2t (n = 10) | 452 \pm 21* | 87 \pm 14 | 0.71 \pm 0.06 |

Group 1 (control): rats dead after 8 months
 Group 2 (initial): orchietomy, rats dead after 30 days
 Group 2 (late): orchietomy, rats dead after 8 months;
 * different from mean of Group 1 (control) ($p < 0.001$)
 ** different from mean of other groups ($p < 0.0001$)

Table 2: Values (mean \pm mean standard deviation, mg/dl) of blood biochemistry tests of rats collected five months after operations.

| Group | Glucose | Cholesterol | | | Triglycerides | |
|-------|--------------|---------------|--------------|-------------|---------------|--------------|
| | | Total | HDL | LDL | | VLDL |
| 1 Y | 125 \pm 33 | 81 \pm 12 | 25 \pm 4.5 | 43 \pm 8 | 12 \pm 3 | 62 \pm 16 |
| 1 A | 149 \pm 25 | 77 \pm 10 | 22 \pm 4.9 | 42 \pm 6 | 12 \pm 4 | 63 \pm 24 |
| 2 Y | 141 \pm 27 | 86 \pm 15 | 26 \pm 4.7 | 51 \pm 10 | 8 \pm 1.5* | 44 \pm 7** |
| 2 A | 130 \pm 15 | 79.9 \pm 11 | 23 \pm 3.7 | 45 \pm 10 | 11 \pm 3 | 57 \pm 15 |

Group 1Y (young): n = 10, control, young rats.
 Group 1A (adult): n = 8, control, adult rats.
 Group 2J (young): n = 10, orchietomy, young rats.
 Group 2A (adult): n = 10, orchietomy, adult rats.
 * different from mean as compared to Group 1Y ($p = 0.005$).
 ** different from mean as compared to Group 1Y ($p = 0.005$).
 HDL: high density lipoprotein; LDL: low density lipoprotein; VLDL: very low density lipoprotein

Table 3: Values (mean \pm mean standard deviation) of mean blood pressure (mmHg) in the tail of rats in groups 1 and 2.

| | Preoperative | Postoperative |
|------------------|-----------------|-------------------|
| All rats | 104.0 \pm 2.9 | |
| Group 1 (n = 12) | | 107.8 \pm 3.4* |
| Group 2 (n = 10) | | 121.1 \pm 6.4** |

Group 1: control and Group 2: orchiectomy.
 * Different from Group 2 ($p = 0.0348$).
 ** Different from the preoperative level ($p = 0.016$).

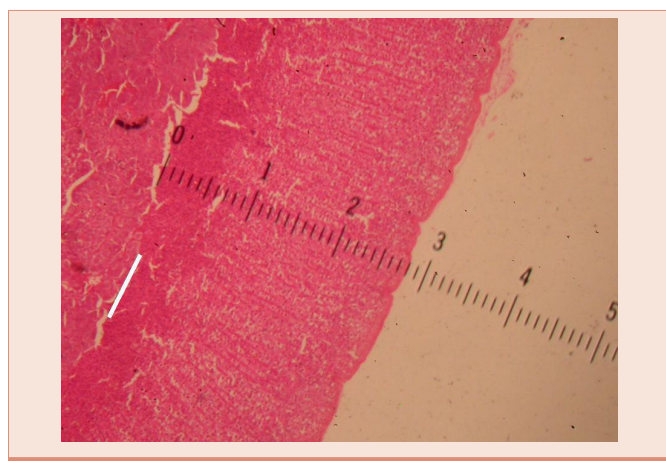


Figure 1: Thickness of the adrenal cortex measured with a ruler calibrated in millimeters.

hormone binding globulin (SHBG), and 60% is bound to albumin in order to become available when necessary. Biological activity is carried out by the 2% of free testosterone. The enzyme, 5-alpha reductase, present in the testicles, metabolizes testosterone to dihydrotestosterone, which is the active androgen in the tissues [1].

In men, testicular Leydig cells secrete more than 95% of the total circulating testosterone, and the rest is produced by the fasciculate and reticular zones of the adrenal glands [7]. Casquero suggested that after castration in mice, there would not be a sufficient quantity of circulating androgens to carry out the functions of this hormone [8].

According to the literature, the effects of testosterone on humans and animals are comparable. The literature is lacking in studies that verify the correlation and comparison of differences between testosterone doses and the observed effects, with a need for higher doses in animals. In this case, our model was effective in suppressing its production - orchiectomy and verify its effects. Since the goal was not to check intensity of dose-related effects, but the change resulting from its maximum suppression, the experimental model can be considered appropriate.

In the study of body weight and adrenal gland morphology, eight months after the operations, the Control Group animals had gained more weight than the orchiectomized rats. In the study performed by Vanderschueren et al., castration did not modify body weight [9]. Snyder et al., also found no weight changes in men with ADAM submitted to hormone replacement [10]. Conversely, Smith et al.,

noted an increased body weight in patients with prostate cancer who had been castrated [7].

Anti-androgenic therapy may affect the metabolism of glucose mediated by modifications of body composition, especially an accumulation of visceral fat. Smith et al., found hyperinsulinemia with normal blood glucose in men with prostate cancer who had been castrated, similar to diabetic patients with increased insulin resistance [11]. The blood glucose of rats in this project was not altered after castration.

Epidemiological data documented the relation between the plasma level of total cholesterol and coronary risk, especially for males under the age of 40 years [12]. Increases in total cholesterol and LDL fraction are factors associated with the higher risk of atherosclerosis and coronary disease, while the increase in HDL is a protective factor. It is known that hypercholesterolemia is significant in more than 50% of patients with cardiovascular diseases, even when considering other local inflammatory disturbances that share responsibility for atherogenesis [13].

Cholesterol is the principal substrate for synthesis of testosterone. According to Isidori et al., there is a reduction in total cholesterol after androgenic therapy in men, with no change in the LDL and HDL fractions [6]. In the present study, castration of the rats did not modify the serum levels of total cholesterol or of its LDL and HDL fractions. Indeed it is difficult to investigate this effect in humans, since unlike animals that may have hydro intake, balanced and controlled food, small differences in human diet can be significant to represent changes in these dosages.

In addition, in this study, orchiectomy in young rats reduced the blood levels of triglycerides and the VLDL cholesterol fraction. Such changes might be indicators of the influence of testosterone on the metabolism of lipids and cholesterol, which still need to be investigated [12,14]. There is an available evidence to support the role of hypertriglyceridemia in atherogenesis, and more recent report highlighting the role of hypertriglyceridemia in the VLDL fraction of cholesterol as well [15].

There is an available evidence to support the role of hypertriglyceridemia in atherogenesis, and more recent report highlighting the role of hypertriglyceridemia in the VLDL fraction of cholesterol as well.

According to the literature, the reduction in free testosterone may be related to changes in the morphology of the adrenal gland [16]. However, in this study, the adrenal cortical thicknesses did not change after orchiectomy.

Cherry et al., in animals with hypogonadism, and Parker et al., in individuals who died from trauma, found no difference in the total adrenal cortical thickness after hypogonadism, although they detected a proportional reduction of the reticular zone relative to the other cortical zones [16,17]. Since testosterone is produced in the testicles and adrenal glands, it is necessary to clarify if the adrenal gland takes on an endocrine compensatory role after orchiectomy.

The invasive method of measuring the arterial pressure in rats requires a continuous infusion of an anticoagulant to maintain blood

flow. The pain caused by the arterial puncture may affect the heart rate and arterial pressure. In order to avoid these inconveniences, it was opted for a non-invasive method. Additionally, the accuracy of non-invasive blood pressure measurements does not differ from that of invasive methods in rats with normal pressure levels, as long as the examiner is qualified and the animal is trained, even considering that invasive methods may be better. A calm environment, adequate acclimatization, and gentle handling of the animals diminish intercurrent factors and increase reliability of measurements [18].

A literature review indicates that the administration of testosterone exacerbates the arterial pressure of previously hypertensive rats and that the castration of these animals reduces the arterial pressure [19,20]. Nevertheless, the same effect was not documented in rats with normal arterial pressure levels. In this study, castration was accompanied by an increase in blood pressure, a result similar to that found by Calhoun et al. [21].

Within Leydig cells, cholesterol is the precursor of sexual hormones and the main substrate for the synthesis of testosterone. During adolescence, the levels of cholesterol fractions HDL and LDL decrease. The levels of HDL are inversely related to testosterone in pubescent boys. These changes during sexual maturation indicate that the sexual hormones participate in the metabolism of the lipoproteins [22].

Some authors reported an increase in the LDL fraction in situations of testosterone deficiency in different species, including hypogonadal humans [23]. The decrease in HDL was observed in studies carried out in hypogonadal men and in castrated mice [24].

On the other hand, an increase or absence of variation of HDL levels also occurred in men with testosterone deficiency, and in castrated monkeys and mice [23].

Some animal studies showed that testosterone possesses a coronary vasodilation action on the thoracic aorta, pulmonary vasculature, and isolated mesenteric veins [25-28]. Testosterone not only induces vasodilatation by the release of nitrous oxide, but also clearly acts in improving sensitivity of smooth vascular muscles to the action of this molecule [29].

Conclusions

Orchiectomy reduces blood levels of triglycerides and VLDL cholesterol in young rats whereas in adult animals, arterial pressure increasing and smaller weight gain are verified.

Acknowledgements

The authors gratefully acknowledge the National Council of Science and Technology (CNPq) and the Foundation for the Assistance to Research of Minas Gerais State (FAPEMIG) for financial support.

References

- Basaria S, Dobs AS (2001) Hypogonadism and androgen replacement in elderly men. *Am J Med* 110: 563-572.
- Bhasin S, Cunningham GR, Hayes FJ, Matsumoto AM, Snyder PJ, et al. (2006) Testosterone therapy in adult men with androgen deficiency syndromes: an endocrine society clinical practice guideline. *J Clin Endocrinol Metab* 91: 1995-2010.
- Lopes EJA (2004) Análise da deficiência androgênica e terapia de reposição em homens idosos [tese]. São Paulo: Universidade de São Paulo.
- Daniell HW, Dunn SR, Ferguson DW, Lomas G, Niazi Z, et al. (2000) Progressive osteoporosis during androgen deprivation therapy for prostate cancer. *J Urol* 163: 181-186.
- Ross RW, Small EJ (2002) Osteoporosis in men treated with androgen deprivation therapy for prostate cancer. *J Urol* 167: 1952-1956.
- Isidori AM, Giannetta E, Greco EA, Gianfrilli D, Bonifacio V, et al. (2005) Effects of testosterone on body composition, bone metabolism and serum lipid profile in middle-aged men: a meta-analysis. *Clin Endocrinol (Oxf)* 63: 280-293.
- Smith MR, Finkelstein JS, McGovern FJ, Zietman AL, Fallon MA, et al. (2002) Changes in body composition during androgen deprivation therapy for prostate cancer. *J Clin Endocrinol Metab* 87: 599-603.
- Casquero AC (2005) Efeitos de hormônios sexuais masculinos sobre o metabolismo das lipoproteínas plasmáticas e expressão da CETP em camundongos geneticamente modificados sedentários e exercitados [tese]. São Paulo: Universidade Estadual de Campinas.
- Vanderschueren D, Vandeput L, Boonen S, Van Herck E, Swinnen JV, et al. (2002) An aged rat model of partial androgen deficiency: prevention of both loss of bone and lean body mass by low-dose androgen replacement. *Endocrinology* 141: 1642-1647.
- Snyder PJ, Peachey H, Hannoush P, Berlin JA, Loh L, et al. (1999) Effect of testosterone treatment on body composition and muscle strength in men over 65 years of age. *J Clin Endocrinol Metab* 84: 2647-2653.
- Yannucci J, Manola J, Garnick MB, Bhat G, Bubley GJ (2006) The effect of androgen deprivation therapy on fasting serum lipid and glucose parameters. *J Urol* 176: 520-525.
- Hak AE, Witteman JC, de Jong FH, Geerlings MI, Hofman A, et al. (2002) Low levels of endogenous androgens increase the risk of atherosclerosis in elderly men: the Rotterdam study. *J Clin Endocrinol Metab* 87: 3632-3639.
- Hansson GK (2001) Immune mechanisms in atherosclerosis. *Arterioscler Thromb Vasc Biol* 21: 1876-1890.
- Weidemann W, Hanke H. Cardiovascular effects of androgens. *Cardiovasc Drug Rev* 20: 175-198.
- Ballantyne CM, Grundy SM, Oberman A, Kreisberg RA, Havel RJ, et al. (2000) Hyperlipidemia: diagnostic and therapeutic perspectives. *J Clin Endocrinol Metab* 85: 2089-2112.
- Parker CR Jr, Mixon RL, Brissie RM, Grizzle WE (1997) Aging alters zonation in the adrenal cortex of men. *J Clin Endocrinol Metab* 82: 3898-3901.
- Cherry BA, Cadigan B, Mansourian N, Nelson C, Bradley EL (2002) Adrenal gland differences associated with puberty and reproductive inhibition in *Peromyscus maniculatus*. *Gen Comp Endocrinol* 129: 104-113.
- Whitesall SE, Hoff JB, Vollmer AP, D'Alecy LG (2004) Comparison of simultaneous measurement of mouse systolic arterial blood pressure by radiotelemetry and tail-cuff methods. *Am J Physiol Heart Circ Physiol* 286: H2408-2415.
- Martin DS, Biloft S, Redetzke R, Vogel E (2005) Castration reduces blood pressure and autonomic venous tone in male spontaneously hypertensive rats. *J Hypertens* 23: 2229-2236.
- Reckelhoff JF (2005) Sex steroids, cardiovascular disease, and hypertension: unanswered questions and some speculations. *Hypertension* 45: 170-174.
- Calhoun DA, Zhu ST, Chen YF, Oparil S (1995) Gender and dietary NaCl in spontaneously hypertensive and Wistar-Kyoto rats. *Hypertension* 26: 285-289.
- Morrison JA, Barton BA, Biro FM, Sprecher DL (2003) Sex hormones and the



- changes in adolescent male lipids: longitudinal studies in a biracial cohort. *J Pediatr* 142: 637-642.
23. Alexandersen P, Christiansen C (2004) The aging male: testosterone deficiency and testosterone replacement. An up-date. *Atherosclerosis* 173: 157-169.
24. Tan KC, Shiu SW, Pang RW, Kung AW (1998) Effects of testosterone replacement on HDL subfractions and apolipoprotein A-I containing lipoproteins. *Clin Endocrinol (Oxf)* 48: 187-194.
25. Deenadayalu VP, White RE, Stallone JN, Gao X, Garcia AJ (2001) Testosterone relaxes coronary arteries by opening the large-conductance, calcium activated potassium channel. *Am J Physiol Heart Circ Physiol* 281: H1720-1727.
26. Ding AQ, Stallone JN (2001) Testosterone-induced relaxation of rat aorta is androgen structure specific and involves K⁺ channel activation. *J Appl Physiol* 91: 2742-2750.
27. Jones RD, Pugh PJ, Jones TH, Channer KS (2003) The vasodilatory action of testosterone: a potassium-channel opening or a calcium antagonistic action? *Br J Pharmacol* 138: 733-744.
28. Tep-areenan P, Kendall DA, Randall MD (2002) Testosterone-induced vasorelaxation in the rat mesenteric arterial bed is mediated predominantly via potassium channels. *Br J Pharmacol* 135: 735-740.
29. Smith JC, Bennett S, Evans LM, Kynaston HG, Parmar M, et al. (2001) The effects of induced hypogonadism on arterial stiffness, body composition and metabolic parameters in males with prostate cancer. *J Clin Endocrinol Metab* 86: 4261-4267.

Copyright: © 2016 Alberti LR, et al. This is an open-access article distributed under the terms of the Creative Commons Attribution License, which permits unrestricted use, distribution, and reproduction in any medium, provided the original author and source are credited.

Citation: Alberti LR, Magalhães Veloso DF, De Souza Vasconcellos L, Carvalho Garcia DP, Petroianu A (2016) Morphofunctional and Metabolic Alterations after Orchiectomy. *Open J Biol Sci* 1: 001-006. DOI: <https://dx.doi.org/10.17352/ojbs.000001>